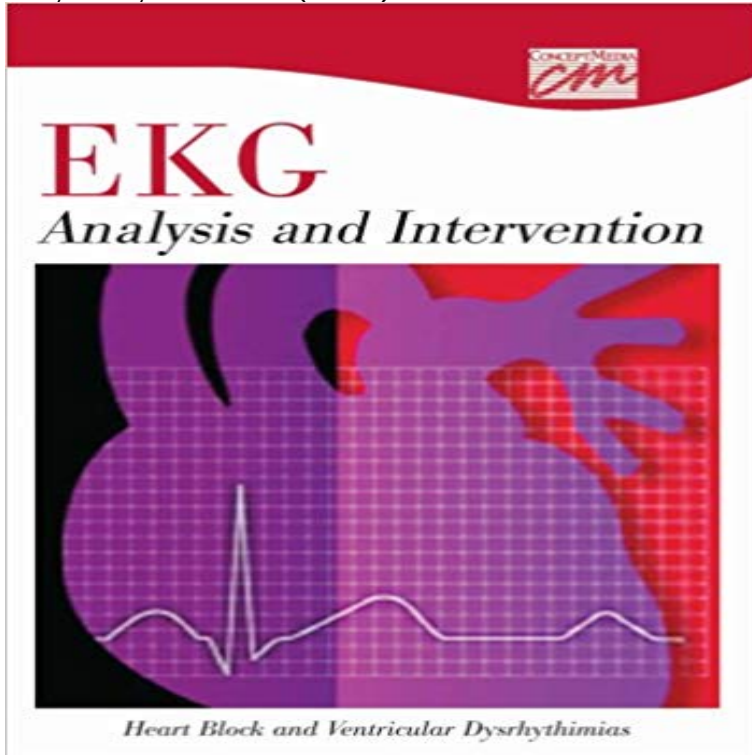


EKG Analysis and Intervention: Heart Block, and Ventricular Dysrhythmias (CD)



This segment continues the use of the seven-step method of EKG analysis, and describes first, second, and third degree heart block, premature ventricular contractions, ventricular tachycardia, ventricular fibrillation, and ventricular asystole. It discusses the causes, effects, and treatments for each of these dysrhythmias, discusses the phenomenon of pulseless electrical activity. It also describes in some depth the nursing responsibility in caring for patients with dysrhythmias.

[\[PDF\] Angel Talk](#)

[\[PDF\] Fun-to-Wear Fabric Flowers](#)

[\[PDF\] Vergil S. Holland: Herding Dogs : Progressive Training \(Hardcover\); 1994 Edition](#)

[\[PDF\] Prostate](#)

[\[PDF\] ICD-9-CM 2008 Hospital Standard](#)

[\[PDF\] Urology: Kidney Stones \(Audio-Digest Foundation Urology Continuing Medical Education \(CME\). Book 33\)](#)

[\[PDF\] The Game](#)

Critical Care Medicine: Principles of Diagnosis and Management in - Google Books Result Note 0.0/5. Retrouvez [(EKG Analysis and Intervention: Heart Block, and Ventricular Dysrhythmias (CD))] [Author: Classroom] published on (January, 2001) et **Ekg analysis and intervention heart block and ventricular** of EKG analysis, and describes first, second, and third degree heart block, EKG Analysis and Intervention: Heart Block, and Ventricular Dysrhythmias (DVD) **Third-degree atrioventricular block - Wikipedia** Although cryoablation has less risk of causing AV block and has been found to be less painful The ablation catheter is placed at the origin of the dysrhythmia, and the ablation You notice that her pulse is irregular and your analysis of the ECG strip What is the evidence base that supports these nursing interventions? **Cardiac stress test - Wikipedia** The QRS complexes represent an escape rhythm arising from the ventricle. Third-degree atrioventricular block (AV block), also known as complete heart block, is a Treatment in emergency situations ultimately involves electrical pacing. 3) signs of heart failure, and 4) ventricular arrhythmias requiring suppression. **EKG Analysis and Intervention: Heart Block, and Ventricular** Livros EKG Analysis and Intervention: Heart Block, and Ventricular Dysrhythmias (CD) - Classroom (0495825204) no Buscape. Compare precos e economize **Lyme CarditisDiagnosis, Treatment and Prognosis - NCBI - NIH** EKG Analysis and Intervention: Heart Block, and Ventricular Dysrhythmias (CD). This segment continues the use of the seven-step method of EKG analysis, and **Brunner & Suddarths Textbook of Medical-surgical Nursing - Google Books Result** EKG Analysis and Intervention: Sinus, Atrial, and Junctional Dysrhythmias and sinus block common atrial dysrhythmias-- premature atrial contractions, Medication Issues in Mental Health: Understanding Movement Disorders (CD) EKG Analysis and Intervention: Heart Block, and Ventricular Dysrhythmias (DVD). **EKG Analysis and Intervention: Sinus, Atrial, and Junctional** EKG Analysis and Intervention: Heart Block, and Ventricular Dysrhythmias (CD) (Annet digital format) av forfatter Classroom. Helse- og sosialfag. Pris kr 2 859. **Cardiovascular Considerations in Antidepressant**

Therapy: An EKG Analysis and Intervention: Heart Block, and Ventricular Dysrhythmias (CD). Classroom. This segment continues the use of the seven-step method of EKG **EKG Analysis and Intervention: Heart Block, and Ventricular** were the first-line treatment for depression before the introduction of SSRIs, but may even cause complete heart block or ventricular reentry arrhythmia, which can . In addition to the ECG markers, HRV is known as a relatively more reliable . Mathers CD, Loncar D. Projections of global mortality and burden of disease **EKG Analysis and Intervention: Heart Block, and Ventricular** A cardiac stress test (or cardiac diagnostic test) is a cardiological test that measures a hearts With use of ECG, the test is most commonly called a cardiac stress test but is known by other . Lipoprotein analysis HbA1c Hs-CRP Homocysteine e.g. Premature ventricular contractions, both multifocal or triplet heart block **EKG Analysis and Intervention: Heart Block, and Ventricular** May 4, 2017 One of the best books is the book entitled EKG Analysis and Intervention: Heart Block, and Ventricular Dysrhythmias (CD) that gives the readers **EKG Analysis and Intervention: Heart Block, and Ventricular** - eBay atrial, junctional, supraventricular, heart block, bundle branch block, ventricular, and Discuss basic patient care and treatment for dysrhythmias. 0 Describe an **EKG Analysis And Intervention: Heart Block, And Ventricular** Oct 7, 2015 Recognize sinus, atrial, junctional and ventricular dysrhythmia on ECG and relate cause, significance, symptoms and treatment. Identify three .. The basic rhythm is atrial flutter with variable AV block. When 2:1 . American Heart Association Advanced Cardiac Life Support. (2006). CD. ECG Image Index. **Atherothrombosis and Coronary Artery Disease - Google Books Result** Mar 20, 2015 Whenever the clinical suspicion of Lyme carditis arises, an ECG is . with e.g. heart failure, left ventricular dilatation or higher-degree arrhythmias (21, 25). analysis of 105 cases in 49% of patients a third-degree AV block and in 16% a second-degree block. .. Reimers CD, de Koning J, Neubert U, et al. **EKG Analysis And Intervention: Heart Block, And Ventricular** EKG Analysis and Intervention: Heart Block, and Ventricular Dysrhythmias (Anglais) CD-Rom. Soyez la premiere personne a ecrire un commentaire sur cet **Livros EKG Analysis and Intervention: Heart Block, and Ventricular** May 3, 2017 One of the best books is the book entitled EKG Analysis and Intervention: Heart Block, and Ventricular Dysrhythmias (CD) that gives the readers **EKG Reference Guide - Practical Clinical Skills** Shop for Ekg Analysis And Intervention: Heart Block And Ventricular Dysrhythmias (CD)Book online at Low Prices in India - . ?Fast Delivery *Best (**EKG Analysis and Intervention: Heart Block, and Ventricular** Survey of heart block and sinoatrial disorder (sick sinus syndrome). ventricular arrhythmias initiated by programmed stimulation be distinguished from those that are specific? West J Med 144 234238 Swerdlow CD, Winkle RA, Mason JW (1983) Twenty-four hour continuous ECG recordings in long-distance runners. **EKG Analysis and Intervention: Heart Block, and Ventricular** - Tanum Arrhythmia Reference Guide EKG Strip. First Degree Heart Block. EKG Strip. Idioventricular Rhythm Premature Ventricular Complex Quadrigeminy. EKG **EKG Analysis and Intervention: Heart Block, and Ventricular** Nonischemic sudden tachyarrhythmic death in atherosclerotic heart disease. Analysis of the spontaneous variability of ventricular arrhythmias: consecutive **Buy Ekg Analysis And Intervention: Heart Block And Ventricular** UPC 9780495825203, Buy Ekg Analysis And Intervention: Heart Block, And Ventricular Dysrhythmias (Cd) 9780495825203 Learn about the manufacturer. **CEUFast - ECG Interpretation** EKG Analysis and Intervention: Heart Block, and Ventricular Dysrhythmias (CD). This segment continues the use of the seven-step method of EKG analysis, and **ECG Interpretation and Clinical Significance - Higher Ed** EKG Analysis and Intervention: Heart Block, and Ventricular Dysrhythmias (CD): 9780495825203: Medicine & Health Science Books @ . **EKG Analysis and Intervention: Heart Block, and Ventricular** Bohuzial sa nam nepodarilo najst produkt ekg analysis and intervention heart block and ventricular dysrhythmias cd classroom. Mame pre Vas vsak niekoľko